

## Paragangliomas of Head and Neck, basic approach

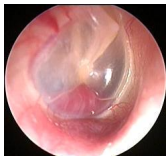Written by Dritan Vassili, MD, Otorhinolaryngologist, Tirana, Albania - Last Updated Sunday, 15 June 2014 08:25

---



**Dritan Vasili,** MD, PhD, ORL, Consultant and Director of ORL Clinic, Hygia Hospital, Tirana, Albania

Paragangliomas are rare neoplasms of neurological origin [neural crest origin] and account for 0.012% of all tumors. Only 10% of them have extraadrenal localization. Head and neck paragangliomas account for 0.33% neoplasms of that localization. Typically paragangliomas are



**Jugulotympanic paraganglioma:** Dritan Vasili, ORL, Tirana, Albania, 2011

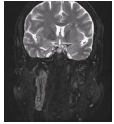
Paragangliomas of the head and neck are highly vascular lesions originating from paraganglionic tissue located at the carotid bifurcation (carotid body tumors), along the vagus nerve (vagal paragangliomas), and in the jugular fossa and tympanic cavity (jugulotympanic paragangliomas). Diagnostic imaging can be considered in two clinical situations:

(1) patients who present with clinical symptoms suggestive of a paraganglioma, and (2) individuals from families with hereditary paragangliomas. It is not only necessary to detect and characterize the lesion, but also to study the presence of multiplicity.

[2]. benign tumors characterized by a strong vascularisation, but even 19% cases may have malignant potential.

On the neck they are located typically closely to carotid artery bifurcation [most commonly occur as carotid body tumors] , jugular bulb and along the course of vagus nerve.

Laryngeal localization is very rare. Nonspecific manifestation and wide spectrum of symptoms cause difficulty in diagnosis of paragangliomas [1].



**Jugulotympanic paraganglioma** Dritan Vasili, ORL, Tirana, Albania, 2011

**"Inheritance" in subjects with SDHD gene mutations.** This means that the disease phenotype may only become present if the mutation is inherited through the paternal line. Boedeker CC. [2011] recommend screening for mutations of the genes SDHB, SDHC and SDHD in all patients with HNPs. Certain clinical parameters can help to set up the order in which the 3 genes should be tested [4] .

Paragangliomas/pheochromocytomas (PGL/PCC) are tumors of the paraganglia. They can occur sporadically, as one sign in a hereditary (tumor) syndrome or as the only manifestation in hereditary PGL/PCC. To date, five forms of hereditary PGL/PCC have been described. They are inherited as autosomal dominant traits and are caused by mutations in genes required for structure and function of complex II of the respiratory chain (succinate-ubiquinone oxidoreductase, succinate dehydrogenase, SDH). Mutations in genes encoding the small subunits of SDH, i.e., SDHD and SDHC, cause PGL1 and PGL3. Mutations in the large subunit genes SDHB, SDHA (currently only one case), and in SDHAF2 cause PGL4, 5, and 2, respectively [5].

The most common and single symptom can be a nonspecific neck mass. Doppler ultrasonography is an adequate diagnostic tool in carotid artery paragangliomas. In order to diagnose multicentric paraganglioma, vagal or laryngeal paraganglioma more thorough radiological examination is necessary, including computed tomography, magnetic resonance and angiography.

Advances in multidetector CT provide exquisite detail with improved delineation of the normal anatomic structures in the head and neck. The carotid body is a structure that is now routinely depicted with this new imaging technique. An understanding of the size range of the normal carotid body will allow the radiologist to distinguish patients with prominent normal carotid bodies from those who have a small carotid body paraganglioma [1].

An ovoid avidly enhancing structure at the inferomedial aspect of the carotid bifurcation within the above range should be considered a normal carotid body. When the carotid body measures

>6 mm, a small carotid body paraganglioma should be suspected and further evaluated [6].

Dopamine excess is present in a considerable percentage of patients with head and neck PGL, and its measurement may be useful in follow-up. Measurement of other catecholamines is necessary to rule out co-existent pheochromocytoma [7].

Complete surgical resection represents the only curative treatment option even though resection of locally advanced tumors regularly results in lesions of the lower cranial nerves and major vessels.

Angiography in combination with embolization will mainly be used prior to surgical resection, but can also be used for diagnostic purposes when the diagnosis is not yet clear. Many parameters play a role in the decision to treat of which multifocality and impairment of cranial nerves are the most important. The primary therapeutic option for paragangliomas is complete excision of tumor with preservation of vital neurovascular structures. Resection however, should be balanced against a more conservative "wait and scan" policy or palliative treatments such as radiotherapy [2].

### References

1. Rzepakowska A, Osuch-Wójcikiewicz E, Kulesza A, Bruzgielewicz A, Niemczyk K. Paragangliomas of the neck--a 10-year experience of the Department of Otolaryngology of Warsaw Medical University. *Otolaryngol Pol.* 2010 Jun;64(7):65-72.

## Paragangliomas of Head and Neck, basic approach

Written by Dritan Vassili, MD, Otorhinolaryngologist, Tirana, Albania - Last Updated Sunday, 15 June 2014 08:25

---

2. van den Berg R. Imaging and management of head and neck paragangliomas. *Eur Radiol*. 2005 Jul;15(7):1310-8. Epub 2005 Apr 5.
  
3. Boedeker CC, Neumann HP, Offergeld C, Maier W, Falcioni M, Berlis A, Schipper J. Clinical features of paraganglioma syndromes. *Skull Base*. 2009 Jan;19(1):17-25.
  
4. Boedeker CC. [Paragangliomas and paraganglioma syndromes]. *Laryngorhinootologie*. 2011 Mar;90 Suppl 1:S56-82. Epub 2011 Apr 26.
  
5. MÃ¼ller U. Pathological mechanisms and parent-of-origin effects in hereditary paraganglioma/pheochromocytoma (PGL/PCC). *Neurogenetics*. 2011 Mar 9.
  
6. Nguyen RP, Shah LM, Quigley EP, Harnsberger HR, Wiggins RH. Carotid Body Detection on CT Angiography. *AJNR Am J Neuroradiol*. 2011 Mar 10.
  
7. Van Der Horst-Schrivers AN, Osinga TE, Kema IP, Van Der Laan BF, Dullaart RP. Dopamine excess in patients with head and neck